CITE PUBLICATIONS

Journal of Medicine and Applied Clinical Sciences

Volume: 2, Issue: 2, 2026 (July - December), Pages: 17-25

ISSN (Online): 3139-5120 | DOI: DOI: https://doi.org/10.67914/jmacs/rsa/2.2/17-25

Research Article

Reproductive Toxicological Effects of Glyphosate on Spermatogenesis and Testicular Histology in Wistar Rats

Oluwaseun Adebayo Ishola[1*], Alfred Abolade Ajao[2], Omotola Ifeoluwa Omotoso[1], Solomon Olayinka Adewoye[3], Christianah Opeyemi Ibikunle[3], Adeyinka Akinyemi[1]

[1]Department of Environmental Health Science, Ajayi Crowther University, Oyo State, Nigeria.
[2]Department of Environmental Health Science, Kwara State University, Kwara State, Nigeria.
[3]Department of Pure and Applied Biology (Environmental Biology Unit), Ladoke Akintola University, Ogbomosho, Oyo State, Nigeria.

[*]**Correspondence**
Oluwaseun Adebayo Ishola
isholaseun4@gmail.com

Creative Commons Attribution-NonCommercial-NoDerivatives 4.0 International (CC BY-NC-ND 4.0).

Received: 14 August 2026 / Accepted: 20 October 2026 / Published: 11 November 2026

Background: Glyphosate is the most widely used herbicide globally, and increasing evidence suggests that chronic exposure may adversely affect male reproductive health. This study investigated the reproductive toxicological effects of glyphosate on spermatogenesis and testicular histology in male Wistar rats.

Methods: Thirty adult male Wistar rats were randomly assigned into six groups (n = 5). Five experimental groups received oral doses of glyphosate at 0.1, 0.3, 0.5, 0.7, and 0.9 mL/kg body weight daily for 28 days, while the control group received normal saline. Semen parameters including sperm motility, viability, count, and morphology were evaluated, and histopathological examination of testicular tissues was performed using hematoxylin and eosin staining.

Results: The results demonstrated significant dose-dependent reproductive toxicity following glyphosate exposure. Sperm motility progressively declined from 80.00 ± 0.95% in the control group to 51.40 ± 0.40% in the highest-dose group, while sperm viability decreased from 79.00 ± 0.84% to 55.80 ± 0.97%. Sperm count was also markedly reduced in exposed groups compared with controls. Furthermore, glyphosate exposure significantly increased sperm abnormalities, indicating disruption of spermiogenesis and impaired sperm maturation. Histological analysis revealed progressive degeneration of seminiferous tubules, germ cell depletion, epithelial disorganization, vacuolization, and interstitial tissue damage, particularly at higher exposure doses.

Conclusion: The findings suggest that glyphosate induces reproductive toxicity through mechanisms involving oxidative stress, mitochondrial dysfunction, endocrine disruption, and structural degeneration of testicular tissues. Overall, this study provides experimental evidence that repeated glyphosate exposure adversely affects spermatogenesis and compromises male reproductive function. These findings raise important public health concerns regarding chronic occupational and environmental exposure to glyphosate, particularly among agricultural workers in developing countries where herbicide use is widespread and poorly regulated.

Keywords: *Glyphosate, spermatogenesis, testicular histology, reproductive toxicity, Wistar rat, male fertility*

Introduction

Glyphosate is currently the most commonly applied herbicide in the world due to its effectiveness in weed control and its significant impact on agricultural productivity. Since it was introduced in the 1970s, glyphosate-based herbicides have become popular applications in many countries, including Nigeria. In Nigeria, herbicides are widely used by farmers to lower labour costs, increase the yield of crops and control weeds during the cultivation season (Chang et al., 2024; Gillezeau et al., 2020). Glyphosate usage is also on the rise in many agriculturally active communities due to the use of modern farm practices and dependence on agrochemicals (Serra et al., 2021; Milesi et al., 2021). Glyphosate was initially thought to be relatively nontoxic to animal and human beings because its mode of action involved a metabolic pathway which was limited to plants and microorganisms, but more and more evidence is emerging to indicate that long-term exposure to the herbicide may represent a severe health risk (particularly the reproductive system) (Serra et al., 2021; Milesi et al., 2021). Human exposure to glyphosate may occur via contaminated food, drinking water, soil, and direct occupational exposure at the time when they are applying the herbicide (Gillezeau et al., 2020). In Nigeria, pesticide misuse, poor use of personal protective equipment, and unsafe storage of pesticides among the farmers have raised concerns about chronic stress of herbicide application and potential adverse health effects (Chang et al., 2024; Giulioni et al., 2022). Several studies in various parts of Nigeria have reported that many farmers are regularly exposed to agrochemicals with little knowledge about the toxicology (Mehrpour et al., 2014; Giulioni et al., 2022). The use of herbicides is increasing both globally and locally and concerns about male reproductive health have increased with the discovery that various environmental pollutants including pesticides, herbicides, heavy metals, and endocrine disruptors are responsible for reduced semen quality and male infertility worldwide (Giulioni et al., 2022; Mehrpour et al., 2014).

The male reproductive system is especially sensitive to toxic agents given that spermatogenesis is a complex and highly regulated process sustained by the normal function of the seminiferous tubules, Sertoli cells, Leydig cells, and reproductive hormones in the testes. The disruption of these structures and/or hormonal pathways may result in a negative impact on sperm production and male fertility (Serra et al., 2021; Milesi et al., 2021). There are concerns about the environmental contamination of agricultural chemicals in Nigeria as a result of increasing applications and the potential adverse effects on reproductive health, particularly given that most of the affected are from rural farming communities with prolonged occupational exposure (Gillezeau et al., 2020). Recently, glyphosate residue was first found in human semen plasma in higher concentrations than in blood plasma and the study found a positive correlation between the glyphosate residue and biomarkers of oxidative DNA damage, which indicate that it could have a direct detrimental effect on male reproductive health (Vasseur et al., 2024). In previous experimental studies conducted on rodents, it was reported that glyphosate exposure could reduce sperm count and sperm motility and viability, cause abnormal sperm morphology, alter hormone levels, and cause damage to the structure of the testes (Valente et al., 2024). Common histological findings include degeneration of seminiferous tubules, loss of germ cells, epithelial disorganization, vacuolisation, and damage to interstitial tissue, which are suggestive of impaired spermatogenesis and testicular function (Serra et al., 2021; Milesi et al., 2021). Several experimental studies in Nigeria investigating the toxicity of pesticides have also shown that exposure to agrochemicals results in changes to reproductive parameters and induction of oxidative stress in lab animals (Avdatek et al., 2018). Although there are large studies on glyphosate toxicity, there is still limited data on the relationship between sperm quality parameters and testicular histopathology after exposure. Most of the earlier studies mainly focused on hormonal and biochemical changes and few have used sperm characteristics with histological changes in testicular tissue. Hence, it is essential to have studies which incorporate both semen analysis and testicular histology to study the toxic effect of glyphosate on the reproductive system of rodents, particularly in a country such as Nigeria where the use of herbicide is on the increase. The Wistar rat is commonly used in reproductive toxicology studies as it has a similar reproductive system to that of humans, with well characterised reproductive physiology. Therefore, the changes in sperm motility, sperm viability, sperm count, sperm morphology, and testicular histology in the Wistar rat model will give us insight into the reproductive toxicological effects of glyphosate. So, the purpose of this study was to look at how glyphosate affects reproduction and testicular tissues in Wistar rats. We used sperm motility, viability, count, morphology, and testicular histology for this.

Materials and Methods

Study design

This study employed an experimental laboratory-based design to evaluate the reproductive toxicological effects of Glyphosate on spermatogenesis and testicular histology in male Wistar rats. The study investigated the effects of varying doses of glyphosate on sperm parameters and testicular tissue architecture following repeated oral expose.

Experimental animals

Adult male Wistar rats weighing between 180–220 g and aged 8–10 weeks were used for this study. The animals were obtained from the Animal House of the Department of Physiology, [Ladoke Akintola University of Technology, Ogbomoso], Nigeria. The rats were housed in clean polypropylene cages under standard laboratory conditions of temperature (22 ± 2°C), relative humidity (50–60%), and a 12 h light/dark cycle. The animals were allowed free access to standard laboratory feed and clean drinking water ad libitum throughout the study period. Prior to commencement of the experiment, the animals were acclimatized for two weeks under laboratory conditions to minimize environmental stress and ensure physiological stability.

Ethical approval

Ethical approval for the study was obtained from the Institutional Animal Research Ethics Committee of [Ladoke Akintola University of Technology, Ogbomoso] in accordance with the guidelines for the care and use of laboratory animals established by the National Institutes of Health (NIH Publication No. 85–23, revised 2011). All experimental procedures were carried out in compliance with internationally accepted ethical standards for animal experimentation.

Chemicals and reagents

Commercial-grade glyphosate herbicide (Force-Up) was purchased from a certified agrochemical distributor in Nigeria. The herbicide formulation contained [insert concentration, e.g., 360 g/L glyphosate isopropylamine salt]. All reagents and chemicals used for laboratory analyses were of analytical grade.

Experimental grouping and treatment

After four weeks of acclimation, thirty (30) adult male Wistar rats were randomly divided into six groups consisting of five animals per group (n = 5)
The exposure concentrations were as follows:

- Groups M-A: 0.1 mL/kg body weight
- Groups M-B: 0.3 mL/kg body weight
- Groups M-C: 0.5 mL/kg body weight
- Groups M-D: 0.7 mL/kg body weight
- Groups M-E: 0.9 mL/kg body weight
- Groups M-F: received normal saline and served as the control group.

Glyphosate was administered orally once daily using an oral gavage for a period of 28 days. The dosage selection was based on previous toxicological studies and calculated according to body weight (mg/kg body weight). Body weights of the animals were recorded weekly throughout the experimental period to monitor weight changes.

Sample collection

At the end of the treatment period, the animals were fasted overnight and anesthetized using ketamine hydrochloride (50 mg/kg body weight). The rats were sacrificed through cervical dislocation, and the testes and epididymides were carefully excised immediately after dissection. The testes were blotted dry, weighed using a sensitive electronic balance, and preserved in 10% neutral buffered formalin for histological examination. The caudal epididymis was processed for semen analysis.

Semen analysis

Sperm motility

Sperm motility was assessed immediately after epididymal extraction. A small portion of the caudal epididymis was minced in warm normal saline to release sperm cells. A drop of the sperm suspension was placed on a clean glass slide and examined under a light microscope at ×400 magnification. Sperm cells showing progressive movement were counted as motile. Results were expressed as percentage motility.

Sperm viability

Sperm viability was determined using eosin-nigrosin staining technique. Briefly, sperm suspension was mixed with eosin–nigrosin stain and smeared on a clean slide. Live sperm cells excluded the stain, whereas dead sperm cells

absorbed the stain. At least 200 sperm cells were counted under the microscope, and viability was expressed as the percentage of live sperm cells.

Sperm count

Sperm count was determined using a Neubauer haemocytometer. Epididymal sperm suspension was diluted appropriately and loaded into the counting chamber. Sperm cells were counted under a light microscope, and sperm concentration was expressed as million sperm cells per milliliter ($\times 10^6$/mL).

Sperm morphology

Sperm morphology was assessed using stained sperm smears examined under oil immersion microscopy. Sperm cells with normal morphology and those with abnormalities such as bent tails, detached heads, curved midpieces, and malformed heads were identified and counted. Results were expressed as percentages of normal and abnormal sperm cells.

Histological examination

Testicular tissues fixed in 10% neutral buffered formalin were processed using standard histological procedures. The tissues were dehydrated in graded alcohol concentrations, cleared in xylene, and embedded in paraffin wax. Sections of approximately 5 µm thickness were obtained using a rotary microtome and stained with hematoxylin and eosin (H&E). The stained sections were examined under a light microscope for histopathological alterations including degeneration of seminiferous tubules, germ cell depletion, epithelial disorganization, vacuolization, interstitial tissue damage, and other structural abnormalities. Photomicrographs were captured using a digital microscope camera.

Statistical analysis

Data obtained from the study were expressed as mean ± standard error of mean (SEM). Statistical analysis was performed using SPSS version 25.0. Differences among experimental groups were analyzed using one-way analysis of variance (ANOVA) followed by Tukey's post hoc test for multiple comparisons. Values of $p < 0.05$ were considered statistically significant.

Results and Discussion

Impact on spermatogenesis and semen quality

The present study demonstrates a clear dose-dependent impairment of spermatogenesis and semen quality following glyphosate exposure. The significant reduction in sperm motility, viability, and count suggests progressive disruption of both testicular and epididymal functions. A marked decline in sperm motility from 80.00 ± 0.95% in the control group to 51.40 ± 0.40% in the 0.9 mL/kg group indicates severe functional impairment of spermatozoa. This reduction is strongly associated with mitochondrial dysfunction and impaired ATP production, which are essential for flagellar movement. Similar findings have been reported by Romano et al. (2010); Romano et al. (2012) and Avdatek et al. (2018); Nerozzi et al. (2020), who demonstrated that glyphosate exposure disrupts mitochondrial respiration and energy metabolism in germ cells, leading to reduced sperm motility and fertility potential.

Table1. Analysis of sperm parameters in male Wistar rats specifically motility, viability, count, and morphology demonstrated that escalating doses of glyphosate (0.1 mg/kg to 0.9 mg/kg) produced distinct effects across four time points

Groups	MOTILITY (%)	VIABILITY (%)	Sperm Count (106/ml)	Sperm with Deformities	Sperm without Deformities
Control	80.00 ± 0.9487	79.00 ± 0.8367	10.56 ± 0.4833	26.80 ± 1.020	174.2 ± 1.114
0.1	75.00 ± 1.000	75.40 ± 0.8718	9.120 ± 0.1020	32.60 ± 0.7483	166.2 ± 1.200
0.3	78.20 ± 1.828	74.80 ± 2.417	8.560 ± 0.0748	39.20 ± 0.8602	162.4 ± 1.030
0.5	70.60 ± 0.8718	77.40 ± 1.077	9.500 ± 0.3406	42.20 ± 1.356	157.8 ± 1.356
0.7	65.20 ± 1.068	58.00 ± 0.5477	7.740 ± 0.0871	52.80 ± 1.158	146.0 ± 1.378
0.9	51.40 ± 0.4000	55.80 ± 0.9695	7.840 ± 0.0678	57.00 ± 0.7071	141.2 ± 1.158

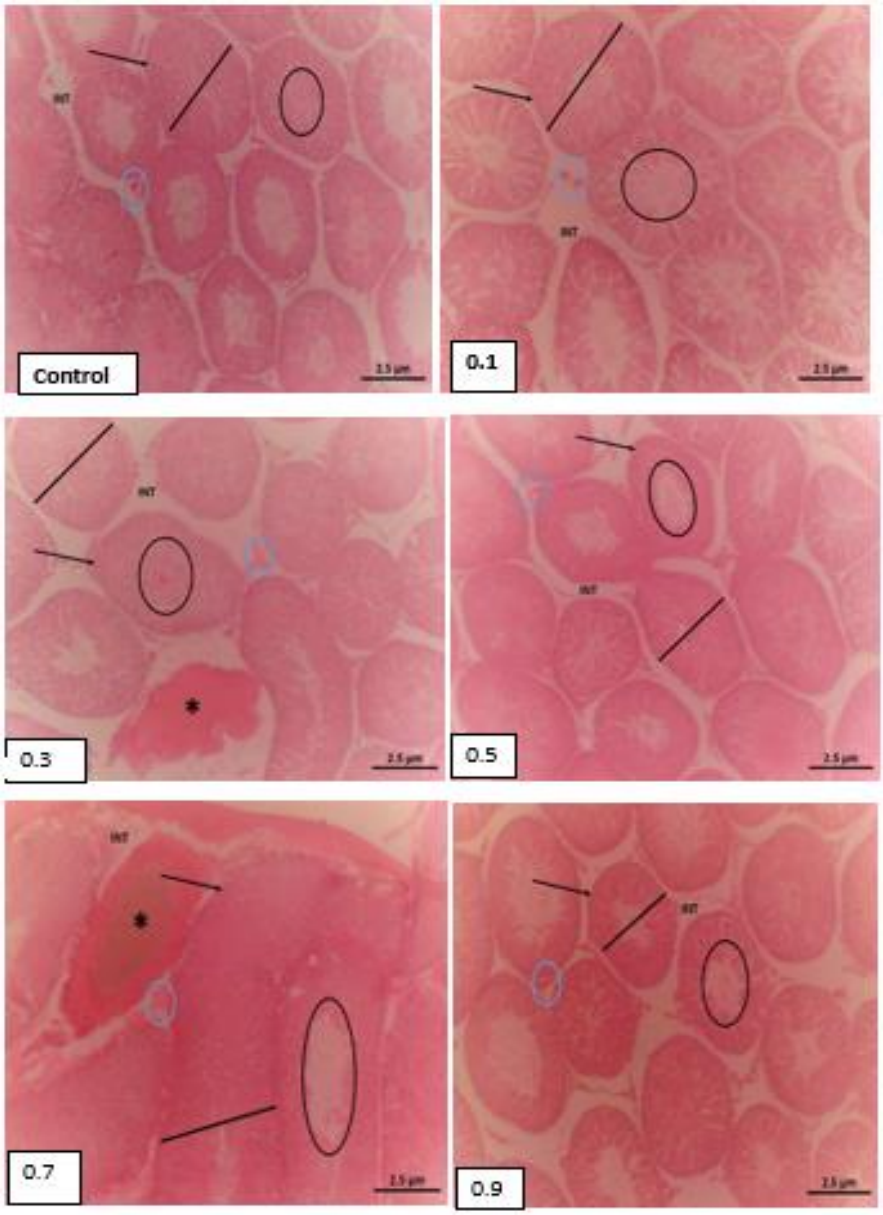

Figure 1. Representative Photomicrograph of Testicular Rats Exposed to Normal Saline (NS), 0.1mg/kg,0.3mg/kg,0.7mg/kg and 0.9mg/kg of Glyphosate Respectively. H&E stain ×100.

Sperm morphology and spermiogenic disruption

The observed increase in sperm abnormalities (26.8 in control vs. 57.0 in high-dose group) indicates disruption of spermiogenesis, particularly during sperm head and tail formation. This suggests glyphosate interference with cellular remodeling processes such as acrosome formation and chromatin condensation. Dai et al. (2016); Owagboriaye et al. (2017) reported that glyphosate induces spermatogenic arrest and structural sperm abnormalities through oxidative damage to developing spermatids. Similarly, Serra et al. (2021); Milesi et al. (2021) highlighted that endocrine disruptors impair spermiogenesis by altering cytoskeletal organization and germ cell maturation pathways.

Histopathological alterations and testicular architecture

Germ cell depletion

The progressive reduction in germ cells and epithelial disorganization observed in this study reflects impaired spermatogonial proliferation. This aligns with findings by Dai *et al*. (2016); Pham *et al*. (2019), who reported that glyphosate exposure disrupts germ cell renewal and leads to depletion of seminiferous epithelium integrity.

Seminiferous tubule degeneration

At higher doses (0.7–0.9 mL/kg), seminiferous tubule degeneration and vacuolization were prominent. This indicates collapse of the spermatogenic microenvironment. Dai *et al*. (2016); Owagboriaye *et al.* (2017) similarly observed tubular degeneration associated with Sertoli cell dysfunction and oxidative injury in glyphosate-exposed testes.

Interstitial tissue and leydig cell damage

The presence of eosinophilic masses and interstitial damage suggests Leydig cell involvement and inflammatory response. Since Leydig cells regulate testosterone synthesis, their impairment may contribute to endocrine dysfunction. Romano et al. (2010); Romano et al. (2012) reported that glyphosate disrupts steroidogenic enzyme expression, leading to reduced testosterone levels and compromised spermatogenesis.

Mechanisms of glyphosate-induced reproductive toxicity

Oxidative stress pathway

Glyphosate induces excessive reactive oxygen species (ROS) production, resulting in lipid peroxidation, protein oxidation, and DNA fragmentation. This oxidative damage compromises sperm membrane integrity and viability. Avdatek et al. (2018); Nerozzi et al. (2020) and Romano et al. (2010); Romano et al. (2012) confirmed oxidative stress as a central mechanism of glyphosate-induced male reproductive toxicity.

Endocrine and metabolic disruption

Glyphosate also disrupts endocrine signaling by interfering with testosterone synthesis and Sertoli cell support functions. This leads to impairment of the blood–testis barrier and arrested germ cell maturation. Furthermore, Dai et al. (2016); Pham et al. (2019) demonstrated that glyphosate alters lipid metabolism and steroidogenesis pathways via disruption of the liver–testis axis, further contributing to reproductive dysfunction.

Integrated interpretation

Overall, the findings indicate that glyphosate exerts a multifactorial toxic effect on male reproductive function by targeting mitochondrial energy production, germ cell integrity, Sertoli cell support, and Leydig cell steroidogenesis.

Comparison with previous studies

The findings of the present study are consistent with several previous experimental investigations demonstrating the reproductive toxicity of glyphosate and glyphosate-based herbicides. Earlier studies conducted by Romano et al. (2022) and Mesnage et al. (2023) reported reductions in sperm concentration, motility, and viability following chronic exposure to glyphosate formulations in rodents. Similar histopathological lesions including seminiferous tubular degeneration, germinal epithelial disruption, and interstitial tissue damage have also been documented in experimental animals exposed to herbicides and other environmental toxicants. The study further strengthens existing evidence by integrating both sperm quality assessment and histological examination. The combination of altered semen parameters and severe microscopic tissue degeneration provides strong evidence that glyphosate-induced reproductive toxicity affects both the functional and structural integrity of the testes. Furthermore, the dose-dependent pattern observed in this study supports the suggestion that prolonged or repeated exposure to glyphosate may progressively impair male fertility potential. This finding is particularly important in developing countries such as Nigeria where herbicide exposure among agricultural workers is frequent and often poorly regulated.

Public health and environmental implications

The widespread use of glyphosate in agriculture raises important public health concerns regarding chronic occupational and environmental exposure. In many Nigerian farming communities, herbicides are commonly handled without adequate protective equipment, thereby increasing the risk of repeated exposure among farmers and agricultural workers. The observed reproductive toxicity in Wistar rats may have implications for human male reproductive health because the mechanisms regulating spermatogenesis are relatively conserved across mammals. Continuous environmental exposure to glyphosate residues through contaminated water, food products, and agricultural practices

may therefore contribute to declining male fertility rates. Additionally, the findings highlight the importance of toxicological surveillance, public health education, and stricter pesticide regulation policies in order to minimize unnecessary exposure to potentially harmful agrochemicals.

Conclusion

The present study demonstrated that repeated oral exposure to glyphosate produced significant dose-dependent reproductive toxicological effects in male Wistar rats. Glyphosate exposure resulted in reduced sperm motility, decreased sperm viability, lower sperm count, and increased sperm abnormalities, indicating impaired spermatogenesis and compromised semen quality. Histopathological examination of the testes further revealed degeneration of seminiferous tubules, germ cell depletion, epithelial disorganization, vacuolization, and interstitial tissue damage, particularly at higher exposure concentrations. These alterations suggest severe disruption of testicular architecture and impaired reproductive function. The findings indicate that glyphosate exerts its reproductive toxicity through multiple mechanisms involving oxidative stress, mitochondrial dysfunction, endocrine disruption, and cellular degeneration within the testes. Overall, the study provides evidence that chronic exposure to glyphosate may negatively affect male fertility potential.

Recommendations

The findings of this study highlight the need for increased awareness among farmers and agricultural workers regarding the potential reproductive health risks associated with chronic glyphosate exposure. The consistent use of appropriate personal protective equipment during herbicide handling and application should be strongly encouraged to minimize occupational exposure. Regulatory agencies should also strengthen policies and monitoring systems governing the use, handling, and environmental management of glyphosate-based herbicides. Furthermore, additional mechanistic and long-term studies are required to elucidate the molecular and oxidative stress pathways involved in glyphosate-induced reproductive toxicity and to determine the reversibility of its adverse effects. Large-scale epidemiological investigations among exposed agricultural populations in Nigeria are equally necessary to establish possible associations between chronic glyphosate exposure and male reproductive dysfunction. Finally, the adoption of safer and more sustainable weed management practices should be promoted to reduce dependence on synthetic herbicides and mitigate their potential public health consequences.

Acknowledgement

The authors acknowledge research laboratory staff of the department of Pure and Applied Biology for releasing equipment used during research.

Author’s contributions

OBA conceptualized the study; OBA, FPO and STA collected and analysed data; OBA supervised the study and drafted the manuscript; All authors approved the manuscript.

Funding

Authors received no funding support from any private or public organization. Resources were pulled together by authors in this study.

Conflict of interest

The authors of this research work declare no conflict of interest whatsoever.

Ethics approval

Each anonymized participant voluntarily enrolled in the study and did complete an informed consent form. The study was approved by the University Ethical Review Committee (UERC) of the University of Ilorin, Nigeria (Approval number: UERC/ASN/2023/2517), and also complied with the Helsinki Declaration on studies involving human subjects.

AI tool usage declaration

The authors not used any AI and related tools to write this manuscript.

References

Dai, P., Hu, P., Tang, J., Li, Y., & Li, C. (2016). Effect of glyphosate on reproductive organs in male rat. *Acta Histochemica, 118*(5), 519–526. https://doi.org/10.1016/j.acthis.2016.05.009

Owagboriaye, F. O., et al. (2017). Reproductive toxicity of Roundup herbicide exposure in male albino rat. *Experimental and Toxicologic Pathology, 69*(7), 461–468. https://doi.org/10.1016/j.etp.2017.04.007

Romano, R. M., Romano, M. A., Bernardi, M. M., Furtado, P. V., & Oliveira, C. A. (2010). Prepubertal exposure to commercial formulation of the herbicide glyphosate alters testosterone levels and testicular morphology. *Archives of Toxicology, 84*(4), 309–317. https://doi.org/10.1007/s00204-009-0494-z

Romano, M. A., Romano, R. M., Santos, L. D., Wisniewski, P., Campos, D. A., de Souza, P. B., Viau, P., Bernardi, M. M., Nunes, M. T., & Oliveira, C. A. (2012). Glyphosate impairs male offspring reproductive development by disrupting gonadotropin expression. *Archives of Toxicology, 86*(4), 663–673. https://doi.org/10.1007/s00204-011-0788-9

Cai, W., Ji, Y., Song, X., Guo, H., Han, L., Zhang, F., Liu, X., Zhang, H., Zhu, B., & Xu, M. (2017). Effects of glyphosate exposure on sperm concentration in rodents: A systematic review and meta-analysis. *Environmental Toxicology and Pharmacology, 55*, 148–155. https://doi.org/10.1016/j.etap.2017.07.015

Mohammadi, K., Alizadeh Sani, M., Safaei, P., Rahmani, J., Molaee-Aghaee, E., & Jafari, S. M. (2022). A systematic review and meta-analysis of the impacts of glyphosate on the reproductive hormones. *Environmental Science and Pollution Research, 29*(41), 62030–62041. https://doi.org/10.1007/s11356-021-16145-x

Avdatek, F., Birdane, Y. O., Türkmen, R., & Demirel, H. H. (2018). Ameliorative effect of resveratrol on testicular oxidative stress, spermatological parameters and DNA damage in glyphosate-based herbicide-exposed rats. *Andrologia, 50*(7), e13036. https://doi.org/10.1111/and.13036

Pham, T. H., Derian, L., Kervarrec, C., Kernanec, P. Y., Jégou, B., Smagulova, F., & Gely-Pernot, A. (2019). Perinatal exposure to glyphosate and a glyphosate-based herbicide affect spermatogenesis in mice. *Toxicological Sciences, 169*(1), 260-271. https://doi.org/10.1093/toxsci/kfz039

Nerozzi, C., Recuero, S., Galeati, G., Bucci, D., Spinaci, M., & Yeste, M. (2020). Effects of Roundup and its main component, glyphosate, upon mammalian sperm function and survival. *Scientific Reports, 10*, 11026. https://doi.org/10.1038/s41598-020-67538-w

Vasseur, C., Serra, L., El Balkhi, S., Lefort, G., Ramé, C., Froment, P., & Dupont, J. (2024). Glyphosate presence in human sperm: First report and positive correlation with oxidative stress in an infertile French population. *Ecotoxicology and Environmental Safety, 278*, 116410. https://doi.org/10.1016/j.ecoenv.2024.116410

Serra, L., Estienne, A., Vasseur, C., Froment, P., & Dupont, J. (2021). Review: Mechanisms of glyphosate and glyphosate-based herbicides action in female and male fertility in humans and animal models. *Cells, 10*(11), 3079. https://doi.org/10.3390/cells10113079

Milesi, M. M., Lorenz, V., Durando, M., Rossetti, M. F., & Varayoud, J. (2021). Glyphosate herbicide: Reproductive outcomes and multigenerational effects. *Frontiers in Endocrinology, 12*, 672532. https://doi.org/10.3389/fendo.2021.672532

Giulioni, C., Maurizi, V., Castellani, D., Scarcella, S., Skrami, E., Balercia, G., & Galosi, A. B. (2022). The environmental and occupational influence of pesticides on male fertility: A systematic review of human studies. *Andrology, 10*(7), 1250–1271. https://doi.org/10.1111/andr.13228

Mehrpour, O., Karrari, P., Zamani, N., Tsatsakis, A. M., & Abdollahi, M. (2014). Occupational exposure to pesticides and consequences on male semen and fertility: A review. *Toxicology Letters, 230*(2), 146–156. https://doi.org/10.1016/j.toxlet.2014.01.029

Ingaramo, P., Alarcón, R., Muñoz-de-Toro, M., & Luque, E. H. (2020). Are glyphosate and glyphosate-based herbicides endocrine disruptors that alter female fertility?. *Molecular and Cellular Endocrinology, 518*, 110934. https://doi.org/10.1016/j.mce.2020.110934

Stone, A. M., Camp, O. G., Biernat, M. M., Bai, D., Awonuga, A. O., & Abu-Soud, H. M. (2025). Re-evaluating the use of glyphosate-based herbicides: Implications on fertility. *Reproductive Sciences, 32*(4), 950–964. https://doi.org/10.1007/s43032-025-01834-6

Chang, V. C., Ospina, M., Xie, S., Andreotti, G., Parks, C. G., Liu, D., Madrigal, J. M., Ward, M. H., Rothman, N., Silverman, D. T., Sandler, D. P., Friesen, M. C., Beane Freeman, L. E., Calafat, A. M., & Hofmann, J. N. (2024). Urinary biomonitoring of glyphosate exposure among male farmers and nonfarmers in the Biomarkers of Exposure and Effect in Agriculture (BEEA) study. *Environment International, 187*, 108644. https://doi.org/10.1016/j.envint.2024.108644

Gillezeau, C., Lieberman-Cribbin, W., & Taioli, E. (2020). Update on human exposure to glyphosate, with a complete review of exposure in children. *Environmental Health, 19*(1), 115. https://doi.org/10.1186/s12940-020-00673-z